

Effect of *Cyperus esculentus* Meal on Glutathione and Sperm Parameters in Androgen-Induced Benign Prostate Hyperplasia (BPH) in Adult Male Wistar Rats

D. I. Izunwanne ^{a*}, D. C. Akukwu ^b, M. U. Elendu ^a, J. N. Egwurugwu ^a,
A. Obialor ^b, C. C. Ofoegbu ^c, H. A. Izunwanne ^d, E. E. Ngwu ^a, G. C. Uloneme ^b
and P. C. Ugwuezumba ^a

^a Department of Human Physiology, Imo State University, Owerri, Nigeria.

^b Department of Human Anatomy, Imo State University, Owerri, Nigeria.

^c Department of Health Sciences, Central Washington College/University of America, Enugu Campus, Nigeria.

^d Department of Public Health, Imo State University, Owerri, Nigeria.

Authors' contributions

This work was carried out in collaboration among all authors. All authors read and approved the final manuscript.

Article Information

Open Peer Review History:

This journal follows the Advanced Open Peer Review policy. Identity of the Reviewers, Editor(s) and additional Reviewers, peer review comments, different versions of the manuscript, comments of the editors, etc are available here: <https://www.sdiarticle5.com/review-history/87602>

Original Research Article

Received 03 April 2022

Accepted 06 June 2022

Published 24 June 2022

ABSTRACT

Introduction: The existence of large population and biodiversity of food plant species has continued to play a prominent role in ensuring healthy lives and promoting longevity for all. This becomes imperative with growing environmental population and its resultant health hazards which may affect the reproductive system. *Cyperus esculentus* may help to cure erectile dysfunction. Infertility is on the increase especially in the developing countries. However, male infertility is commonly due to deficiencies in the semen, and semen quality is used as a surrogate measure of male fecundity.

Aim: The aim of this project was to study the Effect of *Cyperus esculentus* (Tiger Nut) Meal on Glutathione, Some sperm Parameters such as Semen pH, Sperm count, Sperm without a tail, sperm without head etc. and Morphological changes in Androgen-Induced Benign Prostate Hyperplasia (BPH) in Adult Male Wistar Rats.

Methods: A total of sixty (60) male rats weighing between 160 – 200 g were used in this study. They were divided into six groups of ten rats per group. Benign prostate hyperplasia was induced in three groups of the rats (as stated in methodology) with 30 mg/kg sub-cutaneous injections of hormones containing dihydrotestosterone (DHT) and estradiol valerate dissolved in olive oil in the ratio of 10:1 (three times in a week, one day interval). Administration of tiger nut meal commenced immediately and lasted for two months. At the end of administration, blood sample was collected from the rat via cardiac puncture for the determination of Glutathione. Semen samples were collected for analysis of semen abnormality and Cytoplasmic droplets.

Results: Following the induction of BPH, the administration of tiger nut meal showed some positive effects on the rats. On Glutathione, the administration of the tiger nut meal increased the level of the antioxidant, glutathione, in the induced rats ($P < 0.05$). Also, on the effect of the tiger nut meal on the induced abnormalities of the sperm cells (such as sperm cells without a head and the ones without a tail) there was a significantly decreased the level of these abnormalities of the semen recorded following the induction of BPH ($P > 0.05$) while at the same time, enhancing the Sperm concentration (sperm count) ($P < 0.05$).

Conclusion: Tiger nut meal decreased the levels of sperm cells without a head, sperm cells without a tail and that of cytoplasmic complete. It also showed a significant increase in the levels of sperm count, Glutathione and semen pH.

Keywords: *Glutathione; sperm count and sperm abnormalities.*

1. INTRODUCTION

The existence of large population and biodiversity of food plant species has continued to play a prominent role in ensuring healthy lives and promoting longevity for all. This becomes imperative with growing environmental population and its resultant health hazards" [1]. "One of such plants is Tiger nut (*Cyperus esculentus*). Tiger nut has been grossly underutilized and unexploited despite its potentials, which is due to paucity of information and lack of awareness of the composition. Research shows that tiger nut can be a valuable source of nutrients and phytochemicals as it favourably compared with the proximate and mineral composition of some other edible nuts and tubers" [2].

Cyperus esculentus is an annual or perennial plant called chufa sedge, nut grass, a mildly poisonous crop of the sedge family. It is found wild as a weed [3] or as a crop often cultivated for its edible tubers in many countries including Nigeria". "Tiger nut, a tuber with sweet and nutty taste can be consumed raw, roasted, dried or as tiger nut milk or oil" [2]. "It can be stored and rehydrated by soaking without losing the crop texture which ensures acceptable sensory quality [4]. *Cyperus esculentus* may help to cure erectile dysfunction" [5]. This finding was later corroborated by the works of Izunwanne [6].

"Infertility is on the increase especially in the developing countries. However, male infertility is

commonly due to deficiencies in the semen, and semen quality is used as a surrogate measure of male fecundity [7].

Going forward, the link between semen quality and fertility has been studied in humans since 1930 [8]. "Semen analysis, as a standard laboratory test, gives basic information on spermatogenesis, secretory activity of the gonads, patency of the male genital tract and semen morphological aberrations" [9]. The results obtained during the semen sample analysis could point out absence of spermatozoa, severe or mild deviation in sperm parameters or normal values for semen volume, sperm count and concentration, motility and morphology of the spermatozoa. "Over the years many reproductive specialists have been constantly debating, suggesting and remodeling the frame values of the semen in reference to male fertility. Since 1987, there are several updates in different editions of World Health Organization (WHO) manuals defining the optimal sperm parameters with reference to pregnancy outcomes". The fifth edition of the manual, published in 2010, defines serious decrease in cut-off values for sperm parameters related to chances of achieving pregnancy and thus its significance was widely discussed [10,11]. "One of the strong limitations of semen analysis and the defined fertility potential references in the last WHO edition is the lack of correlation with the female age, as only 30% of infertility in couples is due to male factors alone" [12,13].

2. METHODS

2.1 Purchase of Tiger nut and its Authentication

Tiger nut tubers were obtained from the local market at Owerri city, Imo State. The tiger nuts were identified and authenticated at the herbarium of the Department of Plant Science and Biotechnology, Faculty of Natural Sciences, Michael Okpara University of Agriculture, Umudike, Abia State. Its Voucher number is: MOUAU/ZEB/19/004.

For the preparation of tiger nut powder, the tubers were cleaned, washed and dried in a stream of hot air for an hour. The dried tubers were milled using a laboratory electric mill..

2.2 Chemicals and Reagents

All chemicals used were purchased from Sigma Chemicals, St Louis, USA and were of analytical grade. Kits for evaluation of liver and kidney functions, lipid profile and lipid peroxidation were products of Quimica Clinica Aplicada (QCA), Spain.

2.3 Procurement of Experimental Animals

Healthy wistar rats, two months old and weighing 160- 200g were procured from Pharmacology Department, University of Port Harcourt (Rivers State). The rats were housed in wooden netted cages and maintained under environmentally controlled room provided with a 12:12 hours light and dark cycle approximately at 25°C. They were fed on pellets (Lab Feeds) and tap water. The rats were allowed to acclimatize to laboratory environment for 21 days before experimentation. All experimental protocols were subjected to the scrutiny and approval of Institutional Animal Ethics Committee.

2.4 Preparation of Plant Extract

The collected fresh tubers were dried in the shade at 25°C for two weeks and thereafter, was extracted using Soxhlet extractor machine by ethanol at a specific temperature (60°C) for 48 hr as described by Izunwanne [6]. The extract was preserved in the refrigerator until needed and is hereafter referred to as *C. esculentus* extract.

2.5 Acute Toxicity Test

The LD50 of the extracts was determined in rats according using the method of Lorke, [14].

2.6 Preparation of Tiger-Nut Diet and Plan of the Experiments

Tiger-nut meal was prepared as described by Izunwanne [6].

2.7 Experimental Design

Group 1: Normal Control
Group 2: Negative control (BPH)
Group 3: dysfunction + Low dose (10% of meal)
Group 4: dysfunction + high dose (20% of meal)
Group 5: Normal + Low dose (10% of meal)
Group 6: Normal + high dose (20% of meal)

2.8 Induction of Benign Prostate Hyperplasia

The rats in the test groups 2, 3 and 4 weighing between 160 - 200g were induced with BPH as described by Izunwanne [6].

2.9 Collection of Blood Sample

At the end of treatment, the rats were anaesthetized by briefly exposing them to chloroform vapour, and blood sample was collected by cardiac puncture.

2.10 Qualitative Phytochemical Studies on *Cyperus esculentus*

Phytochemical analysis was done using the methods of Trease and Evans [15] and Harborne [16].

2.11 Quantitative Phytochemical Analysis of *Cyperus esculentus*

The quantitative phytochemical analysis of *Cyperus esculentus* was determined using standard methods described by [16,17,18 and 19].

2.12 Semen Collection and Analysis

The sperm cells were harvested from the epididymal reserve. The caudal portion of each epididymis was incised and a smear made on the preheated glass slides for evaluation.

2.12.1 Macroscopic examination

The semen pH were evaluated macroscopically and recorded. The pH scale [1-14], adopted by [20] was used.

2.12.2 Abnormal sperm proportion

The abnormal sperm proportion was determined by the method described by [21].

2.13 Statistical Analysis

Statistical analysis was carried out using windows (SPSS version 15.0). Data were analyzed using one-way ANOVA followed by post hoc test-least significant difference (LSD), while charts were done using Microsoft excel. The data was expressed as mean \pm SEM and values of $p < 0.05$ were considered significant.

3. RESULTS

3.1 Effect on Semen pH [1-14]

Table 1 shows that the level of the semen pH in the normal control group was 6.99 ± 0.05 . After induction of BPH, there was a significant decrease in the level of semen pH of the sperm cells to about (6.48 ± 0.04) in the negative control group ($p < 0.05$).

Treatment of the BPH with the tiger nut meal after induction shows that, at low dose of 10% (7.08 ± 0.01), the level of semen pH increased significantly from 6.48 ± 0.04 in the negative control to 7.08 ± 0.01 in the treatment group. However, treatment with high dose (20%) (6.98 ± 0.05) of tiger nut meal showed same significant increase of the pH level of the semen in the animals ($p < 0.05$).

Again, the administration of tiger nut meal to the rats under normal condition (i.e without induction of BPH) did not show any statistical difference when compared with the normal control ($p < 0.05$).

3.2 Effect on Sperm Concentration (Sperm Count) (ml)

Table 2 shows that the level of the proportion of live sperm in the normal control group was

111.19 ± 2.07 . After induction of BPH, there was a significant decrease in the level of sperm concentration to about (76.48 ± 3.12) in the negative control group ($p < 0.05$).

Treatment of the BPH after induction shows that, at low dose of 10% (100.01 ± 2.62), the level of sperm concentration increased significantly from 76.48 ± 3.12 in the negative control to 100.01 ± 2.62 in the treatment group. However, treatment with high dose (20%) (112.34 ± 1.72) of the tiger nut meal showed more significant increase in the level of the sperm concentration in the animals ($p < 0.05$).

On the effect of administering tiger nut meal to the rats under normal condition, both the low dose and the high dose groups of normal rats, which were not induced with BPH has no statistical difference when compared with the normal control ($p < 0.05$).

3.3 Effect on Glutathione (u/L)

Table 3 shows that the level of the Glutathione in the normal control group was 42.98 ± 0.66 . After induction of BPH, there was a significant decrease in its level to about (35.18 ± 0.84) in the negative control group ($p < 0.05$).

Treatment of the BPH with the tiger nut meal after induction showed that, at low dose of 10% (40.06 ± 0.77), the level of glutathione increased significantly from 35.18 ± 0.84 in the negative control to 40.06 ± 0.77 in the 10% treatment group while that of high dose (20%) increased to 42.73 ± 0.82 at $p < 0.05$.

3.4 Effect of the Tiger Nut Meal on the Sperm Cells without Head (%)

Fig. 1 shows that the level of the sperm cells without a head in the normal control group was 0.43 ± 0.03 . After induction of BPH, there was a significant increase in the number of sperm cells without a head to 0.85 ± 0.02 in the negative control group ($p < 0.05$).

Table 1. Effect of tiger nut meal on the Semen pH in rats

Parameters	Control	Induction Only	Induction + Low dose	Induction + High dose	Low dose (10%)	High dose (20%)
Semen pH (1-14)	6.99 ± 0.05^b	6.48 ± 0.04^a	7.08 ± 0.01^b	6.98 ± 0.05^b	6.95 ± 0.04^b	6.97 ± 0.04^b

Values are mean \pm SEM, $n=10$, parameters in the row with the same alphabet are statistically the same ($p > 0.05$), parameters with different alphabets are statistically difference ($p < 0.05$)

Treatment of the BPH with the tiger nut meal after induction showed that, at low dose of 10% (0.42±0.02) and a high dose (20%) (0.26±0.02) of the tiger nut meal, a significant decrease in the number of the sperm cells without a head was recorded when compared with the negative control of 0.85±0.02 (p < 0.05). The treatment of the said BPH with tiger nut was able to positively restore the morphology of the sperm by improving the quality of the head of the sperm cells. This finding suggests that, tiger nut may have a strong ameliorative effect on the morphological aberration of the sperm head.

Furthermore, the administration of tiger nut meal to the rats under normal condition at low dose of 10% (0.28±0.08) and that of high dose (20%) 0.60±0.03. The high dose has no statistical difference when compared with the normal control (p > 0.05) but that of low dose is statistically different from both the normal control and that of the negative control (P<0.05).

3.5 Effect of the Tiger Nut Meal on Sperm Cells without a Tail (%)

Fig. 2 shows that the level of the sperm cells without a tail in the normal control group was 0.42±0.03. After induction of BPH, there was a significant increase in the level of sperm cells without a tail to 1.16±0.07 in the negative control group (p < 0.05).

Treatment of the BPH with the tigernut meal showed that, at low dose of 10% (0.58±0.07) and a high dose (20%) (0.15±0.05) of the tiger nut meal, a significant decrease in the number of sperm cells without a tail in the sample was

recorded when compared with the negative control of 1.16±0.07 (p < 0.05).

Furthermore, the administration of tiger nut meal to the rats under normal condition at low dose of 10% (0.22±0.07) and that of high dose (20%) 0.23±0.06 also showed no statistical difference when compared with the positive control (p>0.05).

3.6 Effect of the Tiger Nut Meal on Sperm Cells with Cytoplasmic Complete (Cytoplasmic Droplets) (%)

Cytoplasmic droplets are a normal component of mammalian sperm cell but, are merely abnormal, since they cannot and do not undergo maturation in the epididymis. Its presence is indeed indicative of abnormal spermiogenesis and may result in infertility.

Fig. 3 shows that the percentage of the cytoplasmic droplets in the normal control group was 0.67±0.04. After induction, there was a significant increase in the level of cytoplasmic droplet to about 1.05±0.04 in the negative control group (p<0.05).

Treatment of the BPH with the tiger nut meal after induction showed that, at low dose of 10% (0.67±0.09) and a high dose (20%) (0.57±0.02) of the tiger nut meal, a significant decrease in the level of the cytoplasmic droplets were recorded in the animals when compared with the negative control of 1.05±0.04 (p<0.05). Again, on the administration of tiger nut meal to the rats under normal condition, there is however, no statistical difference when the low and high doses therapy is compared with the normal control (p>0.05).

Table 2. Effect of tiger nut meal on the semen pH in rats

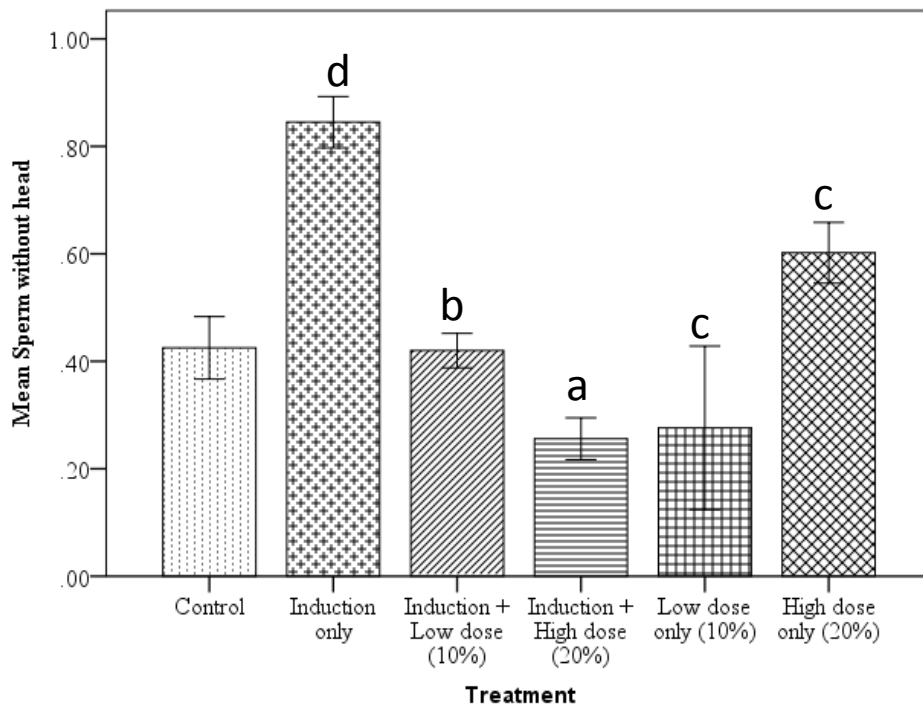
Parameters	Control	Induction Only	Induction + Low dose	Induction + High dose	Low dose (10%)	High dose (20%)
Sperm conc.	111.19±2.07c	76.48±3.12a	100.01±2.62b	112.34±1.72c	118.31±0.69c	109.92±2.9c

Values are mean ± SEM, n=10, parameters in the row with the same alphabet are statistically the same (p>0.05), parameters with different alphabets are statistically difference (p<0.05)

Table 3. Effect of tiger nut meal on the glutathione in rats

Parameters	Control	Induction Only	Induction + Low dose	Induction + High dose	Low dose (10%)	High dose (20%)
Glutathione (u/L)	42.98±0.66 ^c	35.18±0.84a	40.06±0.77 ^b	42.73±0.82bc	45.17±0.62cd	46.1±0.21 ^d

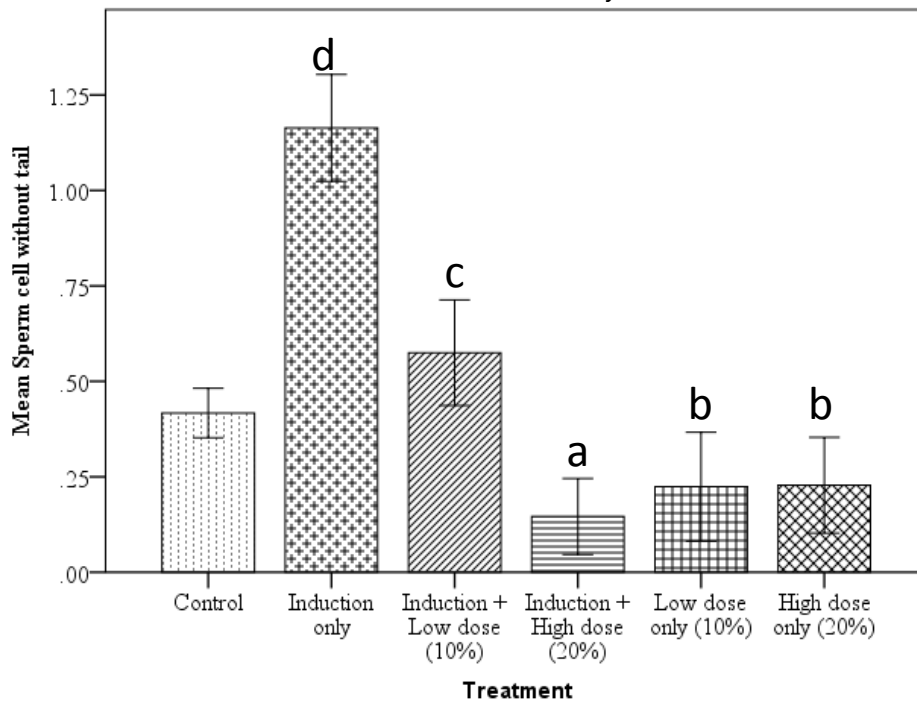
Values are mean ± SEM, n=10, parameters in the row with the same alphabet are statistically the same (p>0.05), parameters with different alphabets are statistically difference (p<0.05)



Values are expressed as mean ± SEM, n=10

Fig. 1. Effect of tiger nut meal on the Sperm without head in rats

d = $P < 0.05$ vs control; b = $P < 0.05$ vs induction only; a = $P < 0.05$ vs induction only; c = $P < 0.05$ vs induction only



Values are expressed as mean ± SEM, n=10.

Fig. 2. Effect of tiger nut meal on the sperm without tail in rats

d = $P < 0.05$ vs control; c = $P < 0.05$ vs induction only; a = $P < 0.05$ vs induction only; b = $P < 0.05$ vs induction only

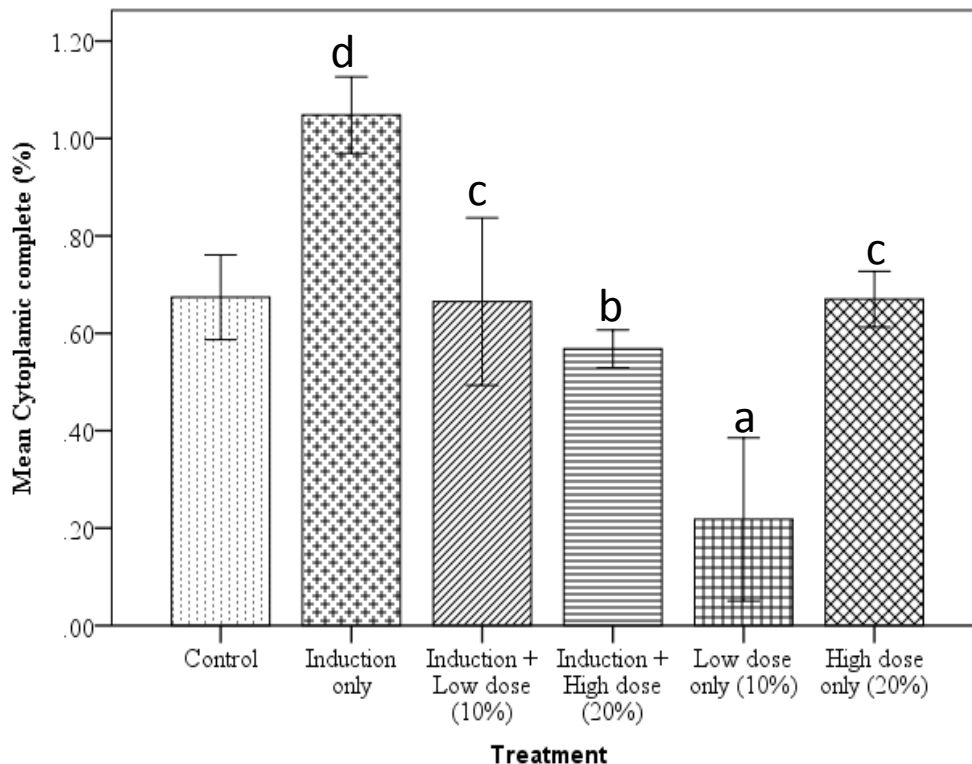
4. DISCUSSION

The effect of *Cyperus esculentus* (tiger nut) on semen parameters namely; semen pH and sperm concentration (count) were studied. The results of these studies showed that tiger nut ameliorated the low levels of semen pH as well as enhancing the sperm concentration in the animals with induced BPH. Furthermore, there was no significant difference noticed in these two parameters in the non-induced animals when compared with the normal controls. This finding showed that tiger nut may more effective in corrective/ameliorating known effects in sperm cells defects. The overall effect/finding may be associated with the increase in testosterone hormone level and is consistent with previous work of Izunwanne [6].

On the effect of *Cyperus esculentus* (tiger nut) on Glutathione antioxidant activity, the result showed a significant increase in the level of glutathione following the administration of tiger nut meal. "Glutathione is a powerful antioxidant that is made in the body's cells. Its levels

decrease as a result of aging, stress and toxin exposure. Boosting glutathione may provide many health benefits against stress and free radicals". "It is the first line of defence against violent attackers of the cells of the human body namely; free radicals, chemical toxins, radiation and heavy metals that enters our body through the environment and the food and liquids we consume, thus, earning the title of master antioxidant".

Generally, studies demonstrate that an antioxidant-rich diet has a very positive health impact in the long run [21,22]. Recently, "antioxidants have attracted considerable attention in relation to radicals and oxidative stress, cancer prophylaxis and therapy, and longevity" [23]. "All the antioxidants are working together as one (antioxidant system), and they are responsible for prevention of the damaging effects of free radicals and toxic products of their metabolism". However, "the antioxidant (team) acts to control levels of free radical formation as a coordinated system where deficiencies in one component impact the efficiency of others" [24].



Values are expressed as mean ± SEM, n=10.

Fig. 3. Effect of tiger nut meal on the cytoplasmic complete (droplets) in rats
d = P < 0.05 vs control; b = P < 0.05 vs induction only; c = P < 0.05 vs induction only; a = P < 0.05 vs control

Sperm cells are fragile and have a long gauntlet to run from the time of manufacture in the testes, until they arrive at their intended destination. They are usually exposed to a subset of free radical compounds known as reactive oxygen species (ROS). "While low levels of ROS play critical role in the normal functioning of sperm cells, an increased concentration can damage the fatty tissue that forms the membrane of the sperm cells resulting in reduced motility and negatively impacting its ability to fuse with a female egg". ROS can also alter sperm DNA, resulting in the passage of defective paternal DNA on the foetus and thus, making a successful pregnancy unlikely. Therefore, "the cumulative and synergistic activities of the bioactive molecules present in the tiger nut meal are responsible for their enhanced antioxidant properties as well as reproductive function".

On the effect of *Cyperus esculentus* (tiger nut) on different sperm cells morphological abnormalities namely; sperm cells without head, sperm cells without tail and cytoplasmic complete (droplets), the results of this study showed that tiger nut ameliorated the high levels of sperm cells without a head, sperm cells without a tail and sperm cells with cytoplasmic complete (droplets). In the non-induced rats, tiger nut also reduced the levels of this same parameters. However, it is imperative to note here that the low dose therapy showed more potent effect than the high dose therapy in significantly reducing the levels of sperm cells without head and cytoplasmic droplets in the rats.

Vast majority of literature on 'cytoplasmic droplets' of human sperm considers them to be indicative of abnormality with sperm being described as of 'diminished maturity' [25] or 'immature sperm' [26]. According to Trevor et al. [27], excess cytoplasmic droplets have been associated with sperm from smokers [28] and men with varicocele [29] and with deficiencies in sperm DNA [30] and phospholipid-bound docosahexanoic acid [29], its presence is indeed indicative of abnormal spermiogenesis. Such sperm should not be described as of 'diminished maturity' [25] or as immature [26], but merely abnormal, since they cannot and do not undergo maturation in the epididymis. The ameliorative effect of the tiger nut meal on the cytoplasmic droplets as well as other morphological defects could be associated with its increased antioxidant effect. Other possible mechanism responsible for the reduced levels of morphological abnormalities of semen

parameters may be associated with the tiger nut enhancing the activities of the Sertoli and Leydig cells of the testes.

5. CONCLUSION

1. Tiger nut meal enhances the pH of the semen.
2. Tiger nut meal enhances the sperm count
3. Tiger nut meal enhances the level of glutathione antioxidant activities
4. Tiger nut meal ameliorates and enhances some of the morphological defect of sperm cell such as sperm cells without a head, sperm cells without a tail and cytoplasmic droplet.

DISCLAIMER

The products used for this research are commonly and predominantly use products in our area of research and country. There is absolutely no conflict of interest between the authors and producers of the products because we do not intend to use these products as an avenue for any litigation but for the advancement of knowledge. Also, the research was not funded by the producing company rather it was funded by personal efforts of the authors.

ETHICAL APPROVAL

All experimental protocols were subjected to the scrutiny and approval of Institutional Animal Ethics Committee.

CONSENT

It is not applicable.

COMPETING INTERESTS

Authors have declared that no competing interests exist.

REFERENCES

- 1 Zhang Y, Huang C, Liu S, Bai J, Fan X, Guo J. Effects of quercetin on intracavernous pressure and expression of nitrogen synthase isoforms in arterial erectile dysfunction rat model. *Int J Clin Exp Med.* 2015;8(5):7599–605.
- 2 Rita ES. The use of tiger nut, cow milk and their composite as substrates for yoghurt production. *Park. J. Nutr.* 2009;6:755758

- 3 Sanchez-Zapata, Juana Fernandez-Lopez and Jose Angel Perez-Alvarez. Tiger nut commercialization: Health Aspects, Composition, Properties and Food Applications. Institute of Food Technologists; 2012.
- 4 Tucson and Arizona. USGS Weed in the West project: Status of introduced plants in Southern Arizona Parks, Factsheets for *Cyperus esculentus* L. 2003;6(5):5449-5454.
- 5 Allouh Z. Mohammed., Haytham M. Daradka and Jamaledin H. Abu Ghaida: Influence of *Cyperus esculentus* tubers (Tiger Nut) on male rat copulatory behaviour. BMC Complementary and Alternative Medicine. 2015;15:331.
- 6 Izunwanne DI, Egwurugwu JN, Emegano CL. Effect of Tiger Nut Meal on PSA, Relative Organ Weight Sperm Cell and Histological Changes in Androgen-induced Benign Prostate Hyperplasia in Adult Male Wistar Rats. European Journal of Medicinal Plants. 2020a;31(15):1-10.
- 7 Cooper TG, Noonan E, von Eckardstein S, Auger J, Baker HW, Behre HM, Haugen TB, Kruger T, Wang C, Mbizvo MT, Vogelsong KM. World Health Organization reference values for human semen characteristics. Human Reproduction Update. 2009;16 (3):231–45.
- 8 Andrade-Rocha FT. On the origins of the semen analysis: A close relationship with the history of the reproductive medicine. Journal of Human Reproduction. 2017; 10(4):242-255.
- 9 Vasani SS. Semen analysis and sperm function tests: How much to test? Indian Journal of Urology. 2011;27(1):41-48. DOI: 10.4103/0970-1591.78424
- 10 Murray KS, Andrew J, McGeady J, Reed ML, Kuang WW, Nangia AK. The effect of the new 2010 World Health Organization criteria for semen analyses on male infertility. Fertility and Sterility. 2012; 98(6):1428-1431. DOI: 10.1016/j.fertnstert.2012.07.1130. [Epub: 24 August 2012]
- 11 Alshahrani S, Aldossari K, Al-Zahrani J, Gabr AH, Henkel R, Ahmad G. Interpretation of semen analysis using WHO 1999 and WHO 2010 reference values: Abnormal becoming normal. First International Journal of Andrology Andrologia. 2018;50(2):128-138. DOI: 10.1111/ and.12838
- 12 Patel A, Leong JY, Ramasamy R. Prediction of male infertility by the World Health Organization laboratory manual for assessment of semen analysis: A systematic review. Arab Journal of Urology. 2018;16:96-102.
- 13 Esteves SC, Zini A, Aziz N, Alvarez JG, Sabanegh ES Jr, Agarwal A. Critical appraisal of World Health Organization's New reference values for human semen characteristics and effect on diagnosis and treatment of subfertile men. Urology. 2012; 79:16-22.
- 14 Lorke D. A. New approach to practical acute toxicity testing. Archives of Toxicology. 1983;54:275-287.
- 15 Harborne, J. B. Phytochemical Methods: A Guide to Modern Technology of Plant Analysis. 2nd Edn. Chapman and Hall, New York. 1983;113.
- 16 Obadoni BO, Ochuko PO. Phytochemical studies and comparative efficacy of the crude extract of some homeostatic plants in Edo and Delta States of Nigeria. Global Journal of Pure and Applied Sciences 2001;8:203-208.
- 17 Boham BA, Kocipai AC. Flavonoids and condensed tannins from the leaves of Hawaiian *Vaccinium vaticulatum*. Pacific Sciences, 1994;48:458 - 463.
- 18 Nabavi SM, Ebrahimzadeh MA, Nabavi, SF, Hamidinia A, Bekhradnia AR. Determination of antioxidant property, phenol and flavonoid contents of *Parotia persica* Mey. Pharmacology Online. 2008;2: 560-567.
- 19 Chibundu UC. Response of pre-pubertal bucks to administration of estradiol B. Project Report, Federal University of Technology, Owerri. 2013;30.
- 20 El-Sherbiny AM. Seasonal variation in seminal characteristics of rabbits. M.Sc. Thesis, Fac. of Agric., Ain-Shams University; 1987.
- 21 Willis LM, Shukitt-Hale B, Joseph JA. Recent Advances in Berry Supplementation and Age-Related Cognitive Decline. Current opinion in clinical nutrition and metabolic care. 2009; 12(5): 91-94
- 22 Sin HPY, Liu DTL, Lam DSC: Life style Modification, Nutritional and Vitamins Supplements for Age-Related Macular Degeneration. Acta Ophthalmologica. 2013;91:6-11.
- 23 Kalcher K, Svancara I, Buzuk M, Vytras K, Walcarius, A. Composition of the human

- semen and of the secretions of the prostate and seminal vesicles. *Am J Physiol.* 2009;136(3):467-473.
- 24 Peter, F.S: Natural Antioxidants in Poultry Nutrition: New Developments. 16th European Symposium on Poultry Nutrition, 2007;669-676.
- 25 Gergely A, Kovanci E, Senturk L, Cosmi E, Vigue L and Huszar G. Morphometric assessment of mature and diminished-maturity human spermatozoa: sperm regions that reflect differences in maturity. *Hum Reprod* 1999;14:2007–2014.
- 26 Ollero M, Powers RD and Alvarez JG. Variation of docosahexanoic acid content in subsets of human spermatozoa at different stages of maturation: implications for sperm lipoperoxidative damage. *Mol Reprod Dev.* 2000;55: 326–334.
- 27 Trevor GC, Ching Yeung, Sabina FA, Eberhard N. Cytoplasmic droplets are normal structures of human sperm but are not well preserved by routine procedures for assessing sperm morphology. *Human Reproduction.* 2004;19(10):2283–2288.
- 28 Mak V, Jarvi K, Buckspan M, Freeman M, Hechter S and Zini A. Smoking is associated with the retention of cytoplasm by human spermatozoa; 2000.
- 29 Zini A, Defreitas G, Freeman M, Hechter S and Jarvi K. Varicoele is associated with abnormal retention of cytoplasmic droplets by human spermatozoa. *Fertil Steril.* 2000;74: 461–464.
- 30 Fischer MA, Willis J and Zini A. Human sperm DNA integrity: correlation with sperm cytoplasmic droplets. *Urology.* 2003;61: 207–211.

© 2022 Izunwanne et al.; This is an Open Access article distributed under the terms of the Creative Commons Attribution License (<http://creativecommons.org/licenses/by/4.0>), which permits unrestricted use, distribution, and reproduction in any medium, provided the original work is properly cited.

Peer-review history:

The peer review history for this paper can be accessed here:

<https://www.sdiarticle5.com/review-history/87602>